Downloaded from www.ajronline.org by 82.152.166.55 on 09/01/25 from IP address 82.152.166.55. Copyright ARRS. For personal use only; all rights reserved

Rotator Cable: MRI Study of Its Appearance in the Intact Rotator Cuff With Anatomic and Histologic Correlation

Soterios Gyftopoulos[1]
Jenny Bencardino[1]
Gregory Nevsky[1]
Gregory Hall[2]
Yousef Soofi[3]
Panna Desai[3]
Laith Jazrawi[2]
Michael P. Recht[1]

OBJECTIVE. The purpose of this study was to define and correlate the appearance of the rotator cable on MRI with arthroscopy, band-saw cadaveric sections, and histology.

MATERIALS AND METHODS. Two cadaveric shoulders underwent 3-T MRI, band-sawing, and histologic evaluation. Three readers evaluated the MRI for the presence of the cable, and the same readers and a pathologist reviewed the macroscopic and microscopic specimens for a structure that corresponded to the cable. Cadaver 1 underwent arthroscopic evaluation to evaluate for the presence of a cable. Seventy consecutive shoulders that underwent 1.5- or 3-T MRI were also reviewed for the presence of the cable and evaluation of its characteristics (location, thickness, and width).

RESULTS. A linear band of hypointense signal intensity was found along the undersurface of the supraspinatus and infraspinatus tendons on both cadaveric MR images, which correlated to a linear band of tissue in the same location on macroscopic and microscopic evaluation and linear thickening along the cuff articular surface on arthroscopy consistent with the cable. The cable was seen in 74.3% of the MRI studies in both sagittal and coronal planes with a mean (± SD) distance of the cable from the medial margin of the enthesis of 1.33 ± 0.27 cm, a mean width of the cable of 1.24 ± 0.31 cm, and a mean thickness of 0.19 ± 0.05 cm.

CONCLUSION. The rotator cable is a structure that can be consistently seen on gross anatomic and histologic analysis, arthroscopy, and MRI in the intact rotator cuff. Familiarity with the typical location and morphology of the cable may allow easier characterization of disease that can involve the cable, such as rotator cuff tears.

Keywords: arthroscopy, cadaveric study, MRI, rotator cable, rotator cuff

DOI:10.2214/AJR.12.9312

Received May 29, 2012; accepted after revision July 25, 2012.

[1]Department of Radiology, NYU Langone Medical Center, 560 First Ave, New York, NY 10016. Address correspondence to S. Gyftopoulos (soterios20@gmail.com).

[2]Department of Orthopaedic Surgery, NYU Langone Medical Center, New York, NY.

[3]Department of Pathology, NYU Langone Medical Center, New York, NY.

AJR 2013; 200:1101–1105

0361–803X/13/2005–1101

© American Roentgen Ray Society

The rotator cable was initially described by Clark and Harryman [1] as a thin fibrous band continuous with the coracohumeral ligament that coursed along the undersurface of the rotator cuff fibers superficial to the joint capsule. This fibrous band had an anterior insertion along the anterior fibers of the supraspinatus and a posterior insertion along the posterior margin of the infraspinatus. It was coined the "rotator cable" a few years later by Burkhardt et al. [2, 3] because of its presumed biomechanical role in the intact and torn rotator cuff tendon, similar to the cables found in suspension bridges. Burkhardt et al. believed that the role of the cable became increasingly more important as a person aged, serving as the primary stabilizer of the rotator cuff tendons [2–4]. At the same time, the cuff fibers lateral to the cable, named the "crescent," became less important while undergoing progressive atrophic change. As long as the cable and its insertions were intact, the rotator cuff fibers would be able to maintain shoulder strength and range of motion even in the presence of full-thickness tearing of the atrophied crescent fibers. If the cable became compromised, then the cuff would lose its main stabilizing structure, leading to progressive, worsening shoulder symptoms.

In the initial descriptions of the cable, it was described as a thick, distinct band that was regularly seen on arthroscopy. The MRI appearance of the rotator cable has not been as consistent. Sheah et al. [5] evaluated the MRI appearance of the cable and concluded that the cable was most consistently seen on abducted and externally rotated (ABER) imaging and in the setting of a partial-thickness tear of the rotator cuff. Kask et al. [6] reported consistent visualization of the cable on MRI, best seen in the axial plane. Morag et al. [7, 8] have shown that the rotator cable can be seen on conventional ultrasound imaging in up to 99% of asymptomatic patients.

Downloaded from www.ajronline.org by 82.152.166.55 on 09/01/25 from IP address 82.152.166.55. Copyright ARRS. For personal use only; all rights reserved

There is no consensus in terms of the MRI appearance of the rotator cable. The purpose of this study is to define and correlate the appearances of the rotator cable on MRI with arthroscopy, band-saw cadaveric sections, and histology.

Materials and Methods

Institutional review board approval was obtained, and informed consent was waived for this retrospective HIPAA-compliant study.

Cadaveric Study

Two shoulders from fresh-frozen cadavers (two women, 52 and 56 years of age) were used for the study. The specimens were labeled 1 and 2, frozen at –9°C, and thawed overnight before imaging. Each specimen underwent MRI (Magnetom Verio 3 T, Siemens Healthcare) examinations after blind injection of saline into the glenohumeral joint. The MRI protocol consisted of coronal oblique, axial, and sagittal oblique T1-weighted (TR/TE, 781/9.5) and proton density (TR/TE, 3000/45) sequences acquired using a 15-channel transmit-receive phased-array knee coil and the following parameters: FOV of 12 × 12 cm, matrix of 256 × 256, bandwidth of 369 Hz/pixel, respective acquisition times of 3 minutes and 23 seconds, and slice thickness of 2 mm (interslice gap, 0%).

After the imaging was completed, the specimens were again frozen at –9°C. One of the cadavers (cadaver 1) underwent arthroscopic evaluation by an orthopedist. Both cadaveric shoulders were subsequently sectioned with a band saw (Biro Model 22, Serial No 37076, Biro Manufacturing), cadaver 1 in the sagittal oblique and cadaver 2 in the coronal oblique planes corresponding to the imaging planes of the MR images. Each section was 5–6 mm thick. The distal 2 cm of the supraspinatus tendon from the coronal and sagittal sections was excised and fixed in 10% formalin for microscopic evaluation. Multiple sections were taken according to the appropriate plane approximately 3 mm thick and 2 cm long, using formalin fixation, paraffin embedding, and 5-μm-thick sections. The sections were then stained with H and E.

The MR images of the shoulder cadavers were evaluated by three musculoskeletal radiologists in consensus for the presence and location of the rotator cable using the following criteria: a hypointense structure continuous with the coracohumeral ligament that coursed along the undersurface of the supraspinatus and infraspinatus tendons perpendicular to the tendon fibers on at least two consecutive images on any of the imaging planes. The MRI findings were then correlated with the findings on the macroscopic evaluation. The histologic sections were then reviewed by the same group of radiologists and one pathologist for the presence of a structure that corresponded to the rotator cable using similar criteria (as mentioned earlier in this article).

Clinical Study

Seventy consecutive 1.5- and 3-T MRI studies of the shoulder (in 41 male and 29 female patients; age range, 3–84 years; mean age, 45 years) with intact rotator cuff tendons were retrospectively collected using a computer data search of all MRI studies performed at our institution during a 2-week period. The patients were chosen irrespective of age, sex, and ethnicity. Thirty-four MRI studies were conducted using a 1.5-T scanner (Siemens), and 36 were conducted using a 3-T scanner (Siemens).

The sequences for the unenhanced 1.5- and 3-T MRI examinations included coronal oblique turbo spin-echo proton density (slice thickness, 3 mm; TR/TE, 2100–2500/25–35) and fat-suppressed T2-weighted (slice thickness, 3 mm; TR/TE, 3500–4000/55–60), sagittal oblique T1-weighted (slice thickness, 3 mm; TR/TE, 450–600) and fat-suppressed T2-weighted (slice thickness, 3 mm; TR/TE, 3500–4000/55–65), and axial fat-suppressed proton density (slice thickness, 3 mm; TR/TE, 2100–2500/25–37). The FOV was 140 mm, and the matrix was 256 × 256 for all the studies. Dedicated 16-channel shoulder array coils were used for imaging.

Two musculoskeletal radiologists (the first reader with 3 years and an additional reader with 1 year of experience in musculoskeletal imaging) reviewed each study independently and documented the presence, location, and size (width and thickness, both in cm) of the rotator cable. Intact tendons were defined as tendons that had no evidence of partial-thickness or full-thickness tearing. The cable was defined as a hypointense structure continuous with the coracohumeral ligament that coursed along the undersurface of the supraspinatus and infraspinatus tendons perpendicular to the tendon fibers on at least two consecutive images on any of the imaging planes. The location of the cable was measured in cm from the medial margin of the cuff footprint to the lateral margin of the cable (Fig. 1). The thickness of the cable was measured in cm from the superior to the inferior margins, whereas the width was measured (also in cm) from the medial to the lateral margins (Fig. 1). Intraclass correlation coefficient (ICC) was used to assess interobserver agreement of the numeric factors.

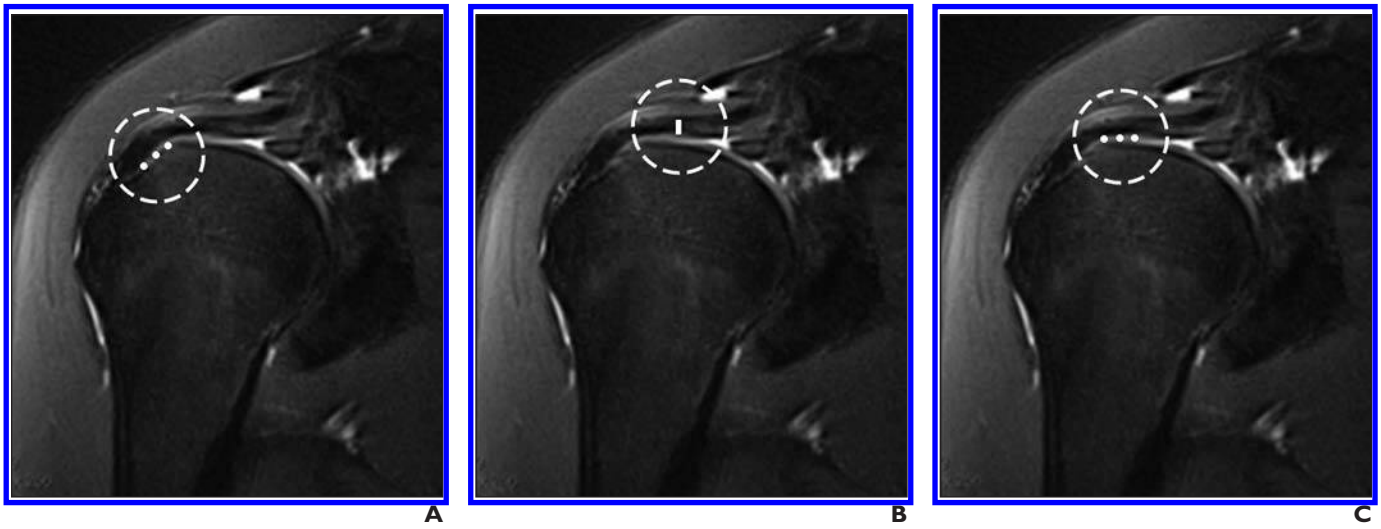

Fig. 1—Rotator cable measurements.
A–C, Location of cable was measured from medial enthesis to its lateral margin (*circle,* **A**), cable thickness was measured from its superior to inferior margins (*circle,* **B**), and width was measured from its medial to lateral margins (*circle,* **C**).

Downloaded from www.ajronline.org by 82.152.166.55 on 09/01/25 from IP address 82.152.166.55. Copyright ARRS. For personal use only; all rights reserved

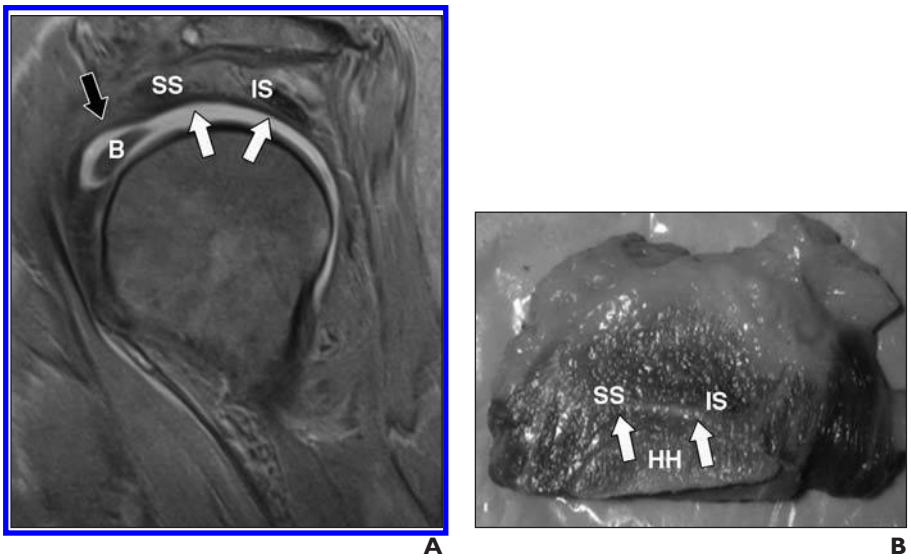

Fig. 2—MRI–gross anatomic correlation in sagittal plane.
A and **B**, Sagittal oblique fast-spin proton density image (**A**) and macroscopic section (**B**) of same region show thin band (*white arrows*) along undersurfaces of supraspinatus (SS) and infraspinatus (IS) tendons that represents rotator cable. Connection of cable with coracohumeral ligament (*black arrow*, **A**) is seen on MRI. B = biceps tendon, HH = humeral head.

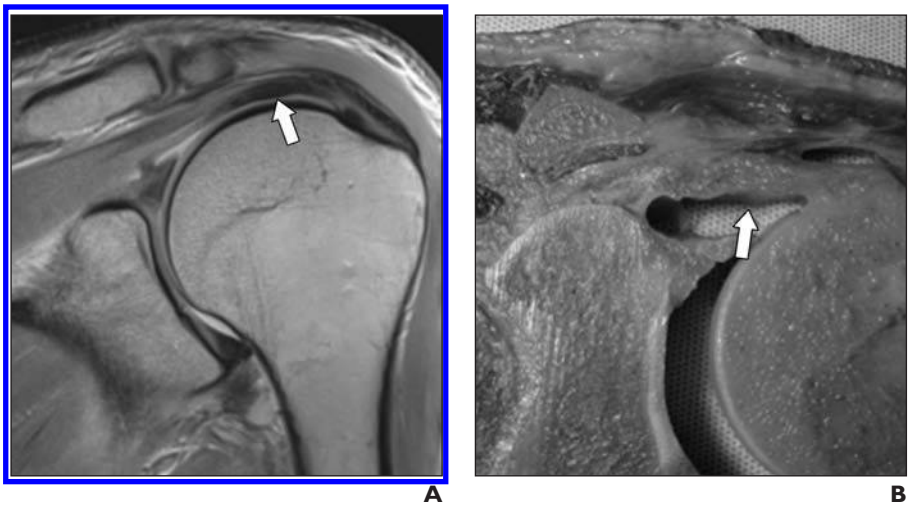

Fig. 3—MRI–gross anatomic correlation in coronal plane.
A and **B**, Coronal oblique fast-spin proton density image (**A**) and macroscopic section (**B**) of same region as in Fig. 2 show focal band (*arrows*) along undersurface of supraspinatus tendon (SS) that represents rotator cable.

Results

Cadaveric Study

A linear band of hypointense signal intensity was found extending posteriorly from the coracohumeral ligament along the undersurface of the supraspinatus and infraspinatus tendons on the MR images of both cadavers (Figs. 2 and 3). In cadaver 1, the rotator cable measured 0.19 cm in thickness by 0.9 cm in width and was found approximately 1.0 cm from the medial margin of the enthesis. In cadaver 2, it measured 0.13 cm in thickness by 0.7 cm in width and was located 1.3 cm from the medial margin of the enthesis. The bands were best visualized on the coronal oblique and sagittal oblique planes. The anterior insertion of each band blended with the anterior margin of the supraspinatus tendon, whereas the posterior insertion was not distinctly seen. These bandlike hypointense structures compatible with the cable on MR arthrographic images correlated with similar-appearing bands of tissue along the undersurface of the supraspinatus and infraspinatus tendons on the macroscopic sections from the sagittal dissection of cadaver 1 (Fig. 2) and the coronal dissection of cadaver 2 (Fig. 3). Histologic examination of the selected sections from the coronal band-sawing showed a bundle of cablelike fibers running perpendicular to the rotator cuff tendon fibers (Fig. 4). The sagittal dissection showed a similar bundle of fibers perpendicular to the cuff tendons (Fig. 4).

Arthroscopic evaluation of cadaver 1 showed a longitudinal, bandlike thickening approximately 1–2 cm from the enthesis along the articular surface of the supraspinatus and infraspinatus tendons that corresponded to the region we denoted as the cable on the MRI study (Fig. 5). The anterior attachment of the cable was easily visualized as it blended with the anterior margin of the supraspinatus tendon (Fig. 6). The posterior insertion was not clearly visualized on arthroscopy. There was no evidence of rotator cuff tearing on either arthroscopy or histologic analysis.

Clinical Study

The rotator cable was seen in 74.3% of the MRI studies. When visualized, the cable was seen on both coronal and sagittal oblique sequences by both readers. The mean (± SD) distance of the cable from the medial margin of the enthesis was 1.33 ± 0.27 cm. The mean width of the cable was 1.24 ± 0.31 cm, and the mean thickness was 0.19 ± 0.05 cm. The ICC for the distance from the medial margin was 0.52; for the cable width, 0.54; and for the cable thickness, 0.63.

Discussion

The rotator cable was initially described in the orthopedic literature as an extension of the

coracohumeral ligament that plays a role in the stability of the torn and intact rotator cuff. The importance of the cable in the choice of treatment of massive rotator cuff tears and painful rotator cuff tears has also been described [9, 10]. The role of imaging in the evaluation of the rotator cable is not as clearly defined.

Using MRI, Sheah et al. [5] were able to identify the rotator cable most consistently on the ABER sequence in both the intact and the torn rotator cuff. The cable was not regularly seen on the non-ABER views, unless there was evidence of partial-thickness or full-thickness tearing. Kask et al. [6] also showed consistent evaluation of the middle portion of the cable (segment found along the undersurface of the supraspinatus tendon) on MRI, most clearly seen in the axial plane. Morag et al. [7] first described the use of ultrasound in the evaluation of the cable. More recently, Morag et al. [8] reported the visualization of the cable in 99% of asymptomatic patients on ultrasound in a wide range of ages.

We were able to identify the rotator cable in our cadaveric specimens on MRI. Both cadaveric specimens underwent band-sawing and histologic evaluation, which also showed the cable in the same location and orientation as observed on the corresponding MRI studies. Arthroscopic evaluation of

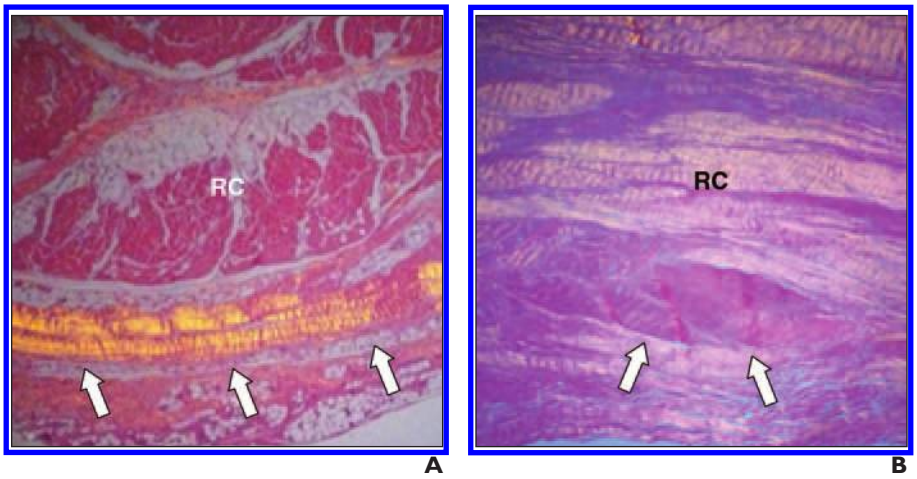

Fig. 4—Histologic evaluation of rotator cable.
A, Sagittal histologic section with polarized microscopy from cadaver 1 specimen shows longitudinal view of rotator cable (*arrows*) coursing perpendicular to rotator cuff tendon fibers (RC).
B, Coronal histologic section with polarized microscopy from cadaver 2 shows cable fibers in cross section perpendicular to rotator cuff fibers (RC) (*arrows*) (H and E stain, × 40).

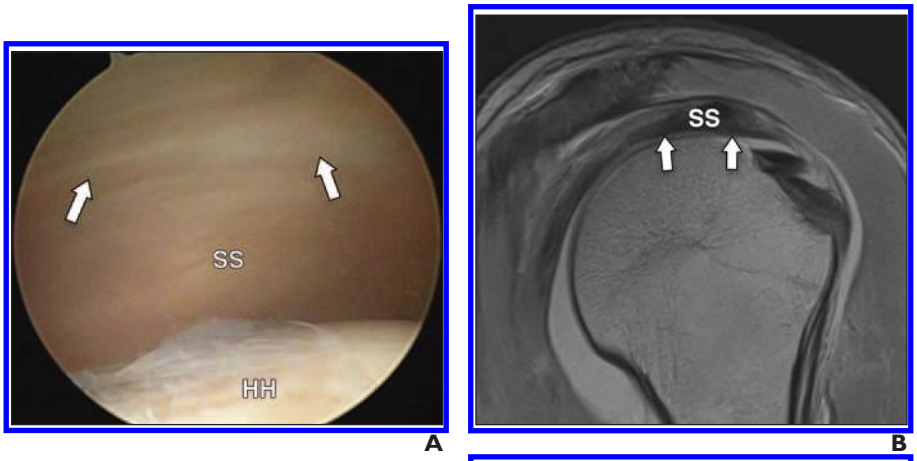

Fig. 5—Arthroscopy of rotator cable.
A, Image from arthroscopy of cadaver 1 visualized from posterior portal shows longitudinal bandlike region of thickening (*arrows*) along articular surface of supraspinatus tendon (SS) consistent with rotator cable. HH = humeral head.
B, Sagittal oblique image from corresponding MRI shows similar band of tissue (*arrows*) along articular surface of supraspinatus tendon (SS) representing cable.

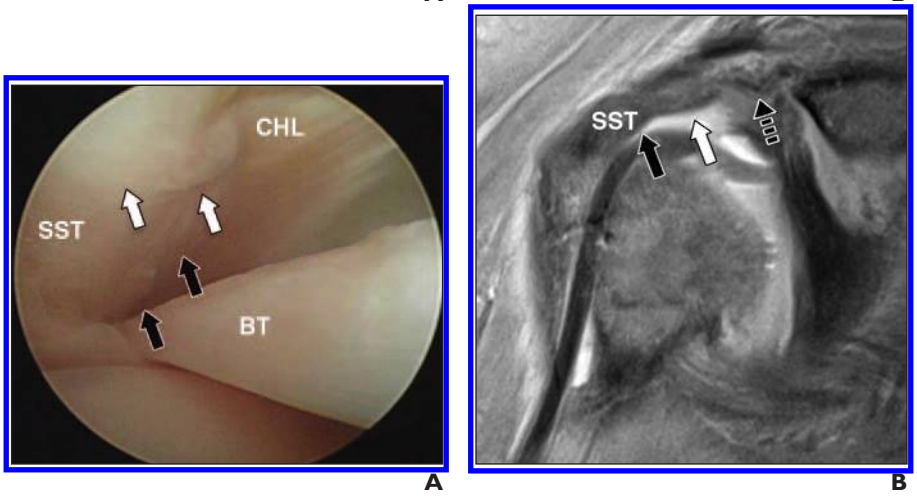

Fig. 6—Anterior insertion of cable on arthroscopy and MRI.
A and **B,** Arthroscopic image obtained from posterior portal (**A**) and corresponding coronal oblique MR image (**B**) show rotator cable (*white arrows*) extending from coracohumeral ligament (CHL; *dashed arrow,* **B**) and its anterior insertion (*black arrows*) along margin of supraspinatus tendon (SST). BT = biceps tendon.

Downloaded from www.ajronline.org by 82.152.166.55 on 09/01/25 from IP address 82.152.166.55. Copyright ARRS. For personal use only; all rights reserved

Downloaded from www.ajronline.org by 82.152.166.55 on 09/01/25 from IP address 82.152.166.55. Copyright ARRS. For personal use only; all rights reserved

cadaver 1 showed the cable along the undersurface of the supraspinatus and infraspinatus tendons in a similar location as the MRI, macroscopic, and histologic evaluations.

We identified the rotator cable in 74.3% of the clinical MRI studies. The cable was most easily and consistently visualized in the coronal and sagittal oblique planes. This increased frequency compared with prior studies was likely secondary to our use of the sagittal oblique images for localization. We first identified the coracohumeral ligament component of the biceps pulley. We then looked for the cable extending from the posterior margin of the pulley along the undersurface of the rotator cuff tendons. Using this as a guide, we could then identify the cable on the coronal oblique images. The morphologic features of the rotator cable were similar to those reported in the ultrasound study by Morag et al. [8] in terms of cable thickness (0.19 cm vs 0.19 cm), width (1.24 cm vs 1.15 cm), and location (1.33 cm vs 1.34 cm).

The realization that the rotator cable can be frequently seen on conventional MRI represents an important first step in understanding its possible biomechanical role in the intact and torn rotator cuff by use of imaging. Becoming familiar with the typical location and morphology of the cable will allow easier characterization of injury or disease that may involve the cable, such as rotator cuff tears. This could, in turn, eventually lead to further studies correlating cable pathology with rotator cuff abnormality such as fatty atrophy, tear size, and tear retraction.

The mean cable thickness in our study differed from that in the original papers by Burkhardt et al. [2–4], where the average cable thickness was reported as 0.47 cm. This was most likely because the original measurements included the adjacent joint capsule and rotator cuff tendon fibers in addition to the cable (Burkhardt S, written communication, 2012).

Our study had several limitations. The study was limited by the small number of cadaveric specimens used for imaging, dissection, and histologic evaluation. Artifacts related to the freezing and sectioning may also have influenced our findings. The retrospective nature of our clinical study and the lack of surgical correlation also limit our study results.

Conclusion

Our study has shown that the rotator cable is a structure that can be consistently seen on gross anatomic and histologic analysis, arthroscopy, and MRI in the intact rotator cuff.

References

1. Clark JM, Harryman DT II. Tendons, ligaments, and capsule of the rotator cuff. *J Bone Joint Surg Am* 1992; 74:713–725
2. Burkhart SS. Fluoroscopic comparison of kinematic patterns in massive rotator cuff tears: a suspension bridge model. *Clin Orthop Relat Res* 1992; 284:144–152
3. Burkhart SS, Esch JC, Jolson RS. The rotator crescent and rotator cable: an anatomic description of the shoulder's "suspension bridge." *Arthroscopy* 1993; 9:611–616
4. Burkhart SS. Reconciling the paradox of rotator cuff repair versus debridement: a unified biomechanical rationale for the treatment of rotator cuff tears. *Arthroscopy* 1994; 10:4–19
5. Sheah K, Bredella MA, Warner JJ, et al. Transverse thickening along the articular surface of the rotator cuff consistent with the rotator cable: identification with MR arthrography and relevance in rotator cuff evaluation. *AJR* 2009; 193:679–686
6. Kask K, Kolts I, Lubienski A, et al. Magnetic resonance imaging and correlative gross anatomy of the ligamentum semicirculare humeri (rotator cable). *Clin Anat* 2008; 21:420–426
7. Morag Y, Jacobson JA, Lucas D, et al. US appearance of the rotator cable with histologic correlation: preliminary results. *Radiology* 2006; 241:485–491
8. Morag Y, Jamadar DA, Boon TA, Bedi A, Caoili EM, Jacobson JA. Ultrasound of the rotator cable: prevalence and morphology in asymptomatic shoulders. *AJR* 2012; 198:W27–W30
9. Burkhart SS, Nottage WM, Ogilvie-Harris DJ, et al. A partial repair of irreparable rotator cuff tears. *Arthroscopy* 1994; 10:363–370
10. Burkhart SS. Arthroscopic debridement and decompression for selected rotator cuff tears: clinical results, pathomechanics, and patient selection based on biomechanical parameters. *Orthop Clin North Am* 1993; 24:111–123